
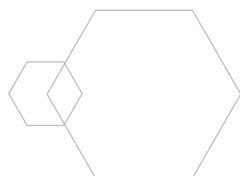




CYTOPLAST[®]



High-Density PTFE Membranes



Why Use Dense PTFE as a Membrane?

PTFE: Polytetrafluoroethylene (PTFE) is comprised of a carbon chain with two fluorine atoms for every carbon atom. The complete fluorination of the carbon chain, along with the strength of the carbon-to-fluorine bonds, makes PTFE highly stable. This stability results in a synthetic polymer that is non-resorbable, biologically inert and chemically non-reactive, and therefore an ideal material for many medical device applications. In addition to its long history in the field of guided tissue regeneration (GTR), PTFE has been used for over 30 years in cardiovascular applications such as suture, vascular grafts and heart valves.

Expanded PTFE: PTFE as a biomaterial differs in porosity based on the amount of expansion applied during manufacturing. Heating PTFE and then applying force expands the material's microstructure to make expanded PTFE (ePTFE). Under scanning electron microscopy, we see a network of dense nodes connected by fibrils. As the nodes and fibrils are expanded, the porosity of the material continues to increase.

Expanded PTFE has a long history of success in GTR procedures, particularly in periodontics. However, the highly porous structure of ePTFE allows ingrowth of bacteria when the membrane is exposed in the mouth. Exposure results in high rates of infection and frequently requires early removal of the device. In addition, the highly porous structure allows soft tissue ingrowth, which complicates removal, often requiring sharp dissection and extensive surgery. Expanded PTFE must be completely buried and primary closure must be maintained to ensure predictability. While expanded PTFE is useful and quite predictable in deep, buried sites for guided tissue regeneration, there is currently no role for this material in extraction site grafting where exposure is likely.

Dense PTFE: Dense PTFE, also known as high-density PTFE or dPTFE, is manufactured to eliminate expansion of the nodes and fibrils, resulting in a micro-porous material that is impervious to bacteria while still allowing diffusion of gases and small molecules. Dense PTFE was designed to withstand exposure in the oral environment, which represents an improvement to earlier versions of ePTFE in many applications, especially socket preservation where deliberate membrane exposure offers several advantages.

Upon implantation, dense PTFE is immediately coated with plasma proteins, facilitating cellular adhesion to the smooth, biocompatible surface. This cellular adhesion is observed to form a hermetic seal, providing resistance to migration of bacteria and epithelial cells around and under the membrane when it is exposed in the mouth. Plasma protein adsorption also facilitates diffusion of soluble organic molecules across the membrane. Removal of dense PTFE is simplified due to the lack of tissue ingrowth into the surface structure.


A textured dense PTFE is available. Texturing the membrane results in an increase in surface area and may increase the pull-out strength of the material through three dimensional attachment of soft tissue. The increased stability in the wound may result in less flap retraction and reduce risk of membrane movement and loosening. The primary advantage of dense PTFE is the ability to remain exposed in the mouth while protecting the underlying defect and bone graft. The membrane is soft, flexible and easy to handle. Primary closure is not required, and the membrane may be removed without additional surgery if exposed. If primary closure technique is used, the membrane may be easily removed through a small incision in a flapless technique.

Dense PTFE is also available with titanium reinforcement, which increases the stiffness of the material for use in defects where space-making is required. The embedded titanium framework allows the membrane to be shaped to fit a variety of defects without rebounding and provides additional stability in large, non-space-making osseous defects.

500X MAGNIFICATION 200 μm 20,000X MAGNIFICATION 5 μm

Expanded PTFE (ePTFE)

High-Density PTFE (dPTFE)



The Evolution of PTFE Membranes

1980s

Gore-Tex® creates the gold standard in barrier membranes.

1994

TefGen-FD®, a smooth bacteria-resistant dense PTFE membrane, is introduced to withstand exposure.^{1,2}

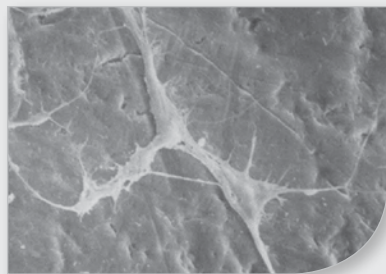
1997-Present

Cytoplast™ dense PTFE membrane becomes an industry leader with advancements such as Regentex™ textured surface technology, multiple shapes and sizes, simple atraumatic removal, and optional titanium reinforcement.³⁻⁷

Unique Properties of Dense PTFE

Impervious to Bacteria: A microbial barrier (strike-through) test was completed by an independent third party lab in accordance with US FDA regulations. The purpose of the test was to verify that the dense PTFE membranes were impervious to bacteria in an accelerated environment. *E. faecalis* was chosen as the challenge organism for its common presence in the oral environment, its spherical morphology, rapid growth, and its small size of 0.5 to 1.0 µm.

The challenge organism was placed on the dense PTFE membranes at a concentration of 2×10^7 (two million) colony forming units per membrane. Ten samples were placed on agar plates and incubated for 48 hours. Following incubation, membranes were removed and agar plates were further incubated for 48 hours, and then bacterial counts were completed on the area underneath the membranes. While all positive controls exhibited growth, all ten test articles exhibited zero growth on the agar plates underlying the dense PTFE membranes. **Reference data on file.*



Cell Attachment: Although PTFE is inherently a non-stick material, cells attach to the outside of the dPTFE membranes. Scanning electron micrographs of removed dPTFE membranes reveal attached fibroblasts to the surface of the dPTFE membranes. Additionally, membrane removal of exposed dPTFE membranes at 21-28 days often results in slight bleeding, which would indicate a biological attachment to the dPTFE membrane. Cellular attachment is important to create a seal around the edges of exposed dPTFE membranes or to support primary closure in larger grafting applications.

1. Bartee BK, Carr JA. Evaluation of a high-density polytetrafluoroethylene (n-PTFE) membrane as a barrier material to facilitate guided bone regeneration in the rat mandible. J Oral Implantol 1995;21:88-95. 2. Bartee BK. The use of high-density polytetrafluoroethylene membrane to treat oral osseous defects: Clinical reports. Implant Dentistry 4:21-32, 1995. 3. Bartee BK. Evaluation of a new polytetrafluoroethylene guided tissue regeneration membrane in healing extraction sites. Compend Contin Educ Dent 1998;19:1256-1264. 4. Barber HD, Lignelli J, Smith BM, Bartee BK. Using a dense PTFE membrane without primary closure to achieve bone and tissue regeneration. J Oral Maxillofac Surg 2007;65:748-752. 5. Hoffman O, Bartee BK, Beaumont C, Kasaj A, Deli G, Zafropoulos GG. Alveolar bone preservation in extraction sockets using non-resorbable dPTFE membranes: A retrospective non-randomized study. J Periodontol 2008; 79: 1355-1369. 6. Fotek PD, Neiva RF, Wang HL. Comparison of dermal matrix and polytetrafluoroethylene membrane for socket bone augmentation: A clinical and histologic study. J Periodontol 2009;80:776-785. 7. Barboza EP, Stutz B, Ferreira VF, Carvalho W. Guided bone regeneration using nonexpanded polytetrafluoroethylene membranes in preparation for dental implant placements – A report of 420 cases. Implant Dent 2010; 19:2-7.

The Cytoplast™ Ridge Preservation Technique

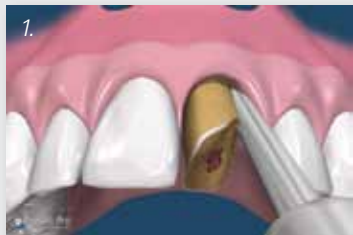


Figure 1. A minimally invasive, atraumatic extraction technique should be used. The use of periostomes or surgical sectioning is encouraged to minimize mechanical trauma to the thin cortical bone. All soft tissue remnants should be removed with a sharp curettage. Special care should be taken to remove residual soft tissues at the apical extent of the socket of endodontically treated teeth. Bleeding from the socket walls should be noted and, if necessary, decortication of the socket wall can be done with a #2 round burr to increase early vascularization and access to osteo-progenitor cells.

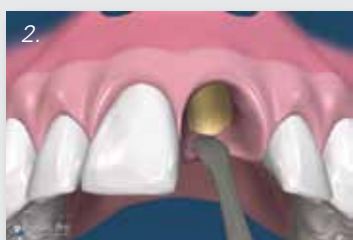

Figure 2. A subperiosteal pocket is created with a small periosteal elevator or curette, extending 3-5 mm beyond the socket margins (or defect margins) on the palatal and the facial aspect of the socket. In the esthetic zone, rather than incising and elevating the interdental papilla, it is left intact and undermined in a similar fashion. The d-PTFE membrane will be tucked into this subperiosteal pocket.

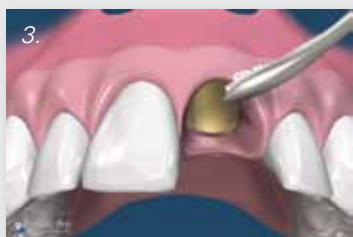
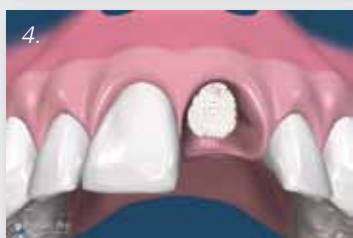
Figure 3 - 4. Particulate augmentation material is placed into the socket with a syringe or curette. Ensure that the material is evenly distributed throughout the socket, but not condensed or packed too tightly. This will only reduce the available space between particles, which is critical for vascular ingrowth and subsequent bone formation.



The Cytoplast™ Ridge Preservation Technique

Figure 5 - 6. The d-PTFE membrane is trimmed to extend 3-5 mm beyond the socket walls and then tucked subperiosteally under the palatal flap, the facial flap, and underneath the interdental papilla with a curette. The membrane should rest on bone 360° around the socket margins, if possible. Note that minimal flap reflection is necessary to stabilize the membrane. Prior to suturing, ensure that there are no folds or wrinkles in the membrane and that it lies passively over the socket. Remove any stray bone graft particles that may be present between the membrane and the flap. To prevent bacterial leakage under the membrane, take care to avoid puncturing the membrane, and do not overlap two adjacent membranes.

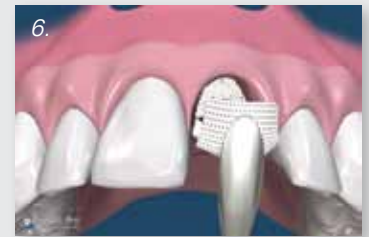
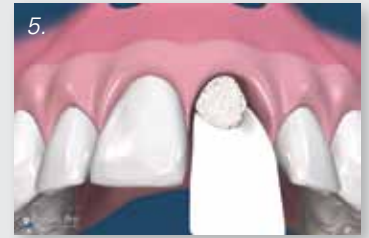
Figure 7. The membrane is further stabilized with a criss-cross PTFE suture. It is not recommended to suture through the membrane. Alternatively, interrupted sutures may be placed. The PTFE sutures, which cause minimal inflammatory response, are left in place for 10 to 14 days.

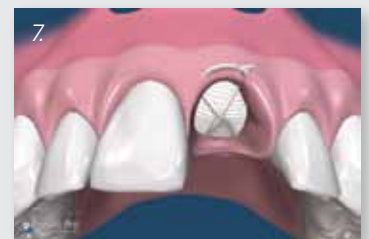

Figure 8. The membrane is removed, non-surgically, in 21 - 28 days. With intact sockets, the membrane may be removed as early as 3 weeks. Studies have shown that by 21-28 days there is a dense, vascular connective tissue matrix in the socket and early osteogenesis is observed in the apical 2/3 of the socket. Sockets with missing walls may benefit from a longer time frame. Topical anesthetic is applied, and then the membrane is grasped with a tissue forcep and simply removed with a gentle tug.

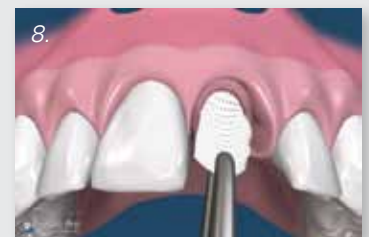
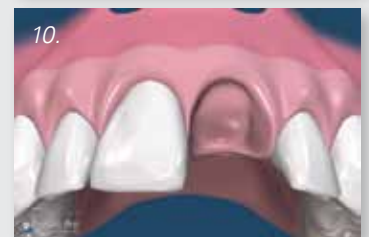
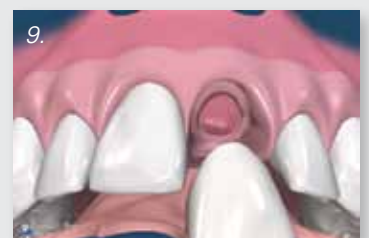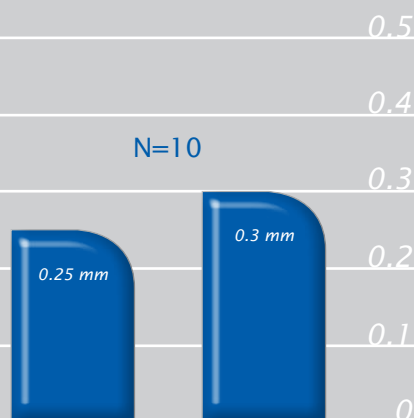
Figure 9 - 10. Immediately following membrane removal, a dense highly vascular osteoid matrix is observed filling the socket. Adjacent gingival epithelium migrates across the osteoid matrix upon removal of the membrane. At 6 weeks, thick keratinized gingiva is beginning to form over the grafted socket. The natural soft tissue architecture is preserved, including the interdental papillae. New bone is beginning to form in the socket.



Clinical Evidence

Predictability: In two separate studies treating a total of 696 extraction sites using Cytoplast™ dPTFE membranes in an exposed technique, there were no reported infections.^{9,12}

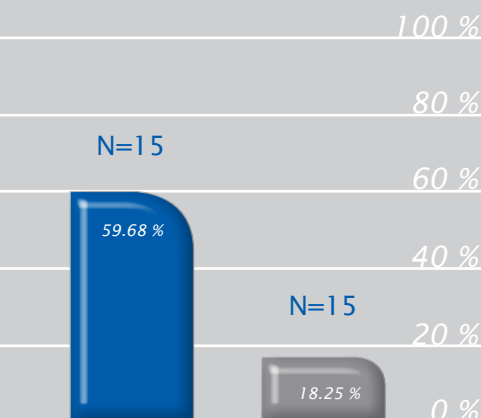
Efficacy: Bone loss 1-year post-extraction using The Cytoplast™ Technique for socket preservation.¹¹



1. Vertical Bone Loss | 2. Horizontal Bone Loss

*Vertical measured at crest. Horizontal measured from stent to buccal plate.

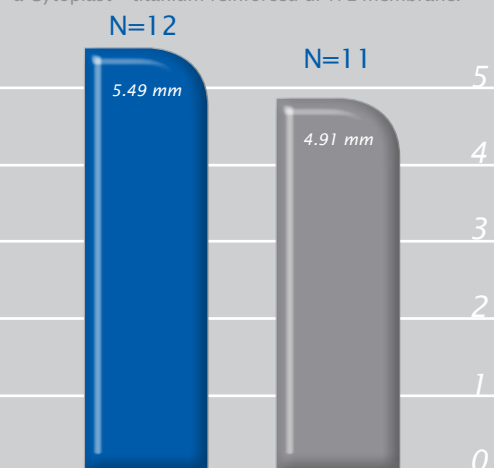
Soft tissue regeneration after extraction using The Cytoplast™ Technique for socket preservation.¹³



1. Cytoplast™ TXT-200 | 2. No Membrane

*Measurements taken at time of extraction and 90 days post extraction.

Vertical ridge augmentation around implants using a titanium-reinforced ePTFE membrane vs. a Cytoplast™ titanium-reinforced dPTFE membrane.³



1. Cytoplast™ Ti-250 dPTFE | 2. ePTFE

*Mean vertical bone regeneration.

Applicable References

- Urban IA, Lozada JL, Jovanovic SA, Nagursky H, Nagy K. Vertical Ridge Augmentation with Titanium-Reinforced, Dense-PTFE Membranes and a Combination of Particulated Autogenous Bone and Anorganic Bovine Bone-Derived Mineral: A Prospective Case Series in 19 Patients. *Int J Oral Maxillofac Implants*. 2014 Jan-Feb;29(1):185-93.
- Carbonell JM, Martin IS, Santos A, Pujol A, Sanz-Molina JD, Nart J. High-density polytetrafluoroethylene membranes in guided bone and tissue regeneration procedures: a literature review. *Int J Oral Maxillofac Surg*. 2014 Jan;43(1):75-84.
- Ronda M, Rebaudi A, Torelli L, Stacchi C. Expanded vs. dense polytetrafluoroethylene membranes in vertical ridge augmentation around dental implants: a prospective randomized controlled clinical trial. *Clin Oral Implants Res*. 2013; (Epub ahead of print).
- Waasdorp, J, Feldman, S. Bone regeneration around immediate implants utilizing a dense polytetrafluoroethylene membrane without primary closure: a report of 3 cases. *J Oral Maxillofac Surg*. 2013;71:355-361.
- Al-Hezaimi K, Rudek I, Al-Harman KS, Javed F, Nooh N, Wang HL. Efficacy of using a dual layer of membrane (dPTFE placed over collagen) for ridge preservation in fresh extraction sites: a micro-computed tomographic study in dogs. *Clin Oral Implants Res*. 2012; (Epub ahead of print).
- Annibaldi S, Bignozzi I, Sammartino G, La Monaca G, Cristalli MP. Horizontal and vertical ridge augmentation in localized alveolar deficient sites: a retrospective case series. *Implant Dent*. 2012 Jun;21(3):175-185.
- Yun JH, Jun CM, Oh NS. Secondary closure of an extraction socket using the double-membrane guided bone regeneration technique with immediate implant placement. *J Periodontol*. 2011;41:253-258.
- Park SY, Kye SB, Yang SM, Shin SY. The effect of non-resorbable membrane on buccal bone healing at an immediate implant site: an experimental study in dogs. *Clin. Oral Impl. Res.* 22, 2011; 289-294.
- Barboza EP, Stutz B, Ferreira VF, Carvalho W. Guided bone regeneration using nonexpanded polytetrafluoroethylene membranes in preparation for dental implant placements - a report of 420 cases. *Implant Dent*. 2010;19:2-7.
- Lee JY, Kim YK, Yun PY, Oh JS, Kim SG. Guided bone regeneration using two types of non-resorbable barrier membranes. *J Korean Assoc Oral Maxillofac Surg*. 2010;36:275-9.
- Fotek PD, Neiva RF, Wang HL. Comparison of dermal matrix and polytetrafluoroethylene membrane for socket bone augmentation: a clinical and histologic study. *J Periodontol* 2009;80:776-785.
- Hoffman O, Bartee BK, Beaumont C, Kasaj A, Deli G, Zafropoulos GG. Alveolar bone preservation in extraction sockets using non-resorbable dPTFE membranes: A retrospective non-randomized study. *J Periodontol* 2008;79:1355-1369.
- Barboza EP, Francisco BS, Ferreira VF. Soft tissue enhancement using non-expanded PTFE membranes without primary closure [abstract]. Presented at the 2008 Research Forum Poster Session. Annual Meeting of the American Academy of Periodontology (AAP) in Seattle, WA, September 6-9, 2008.
- Barber HD, Lignelli J, Smith BM, Bartee BK. Using a dense PTFE membrane without primary closure to achieve bone and tissue regeneration. *J Oral Maxillofac Surg* 2007;65:748-752.
- Walters SP, Greenwell H, Hill M, Drisko C, Pickman K, Scheetz JP. Comparison of porous and non-porous teflon membranes plus a xenograft in the treatment of vertical osseous defects: A clinical reentry study. *J Periodontol* 2003;74:1161-1168.
- Bartee BK. Extraction site reconstruction for alveolar ridge preservation Part 1: Rationale and material selection. *J Oral Implantol* 2001;27:187-193.
- Bartee BK. Extraction site reconstruction for alveolar ridge preservation Part 2: Membrane-assisted surgical technique. *J Oral Implantol* 2001;27:194-197.
- Lamb JW III, Greenwell H, Drisko C, Henderson RD, Scheetz JP, Rebitski G. A comparison of porous and non-porous teflon membranes plus demineralized freeze-dried bone allograft in the treatment of class II buccal/lingual furcation defects: A clinical reentry study. *J Periodontol* 2001;72:1580-1587.
- Bartee BK. Evaluation of a new polytetrafluoroethylene guided tissue regeneration membrane in healing extraction sites. *Compend Contin Educ Dent* 1998;19:1256-1264.
- Bartee BK. The use of high-density polytetrafluoroethylene membrane to treat osseous defects: Clinical reports. *Implant Dent* 1995;4:21-26.

Cytoplast™ Dense PTFE Membranes

Membranes shown actual size



Anterior Narrow



Anterior Singles



Buccal



Posterior Large




Posterior Large T²



TXT-200
Singles



Posterior Singles



Posterior Singles T²



XLK



XL



TXT-200



Cytoplast™ Titanium-Reinforced Dense PTFE Membranes

Available in Cytoplast™
Titanium-Reinforced Ti-250 or Ti-150*

**Ti-150 membranes are 40% thinner
than Ti-250 membranes, providing
clinicians another handling option.*



Cytoplast™ Dense PTFE Membranes

OSTEOGENICS

B I O M E D I C A L

4620 71st Street | Building 78-79
Lubbock, TX 79424